

SUSPECTED HIP DYSPLASIA IN A RED FOX

Dennis F. Lawler,^{1,2} Richard H. Evans,² Jennifer A. Reetz,³ Jill E. Sackman,⁴ Gail K. Smith³

¹Illinois State Museum Collections Center, 1011 East Ash St, Springfield IL 62703

²Pacific Marine Mammal Center, 20612 Laguna Canyon Rd, Laguna Beach CA 92651

³Department of Clinical Studies, School of Veterinary Medicine, 3900 Spruce St., Philadelphia PA 19104

⁴Numerof & Associates, Inc., Four City Place Drive, Suite 430, St. Louis MO 63141

email: dlawler11@yahoo.com

ABSTRACT: We report skeletal features that are consistent with hip dysplasia, as it is described in domestic dogs (*Canis lupus familiaris*) in a museum specimen of a red fox (*Vulpes vulpes*). Morphological identifiers included shallow acetabulae, femoral head flattening and subluxation, caudal curvilinear osteophyte, circumferential femoral head osteophyte, osteophytes of the acetabular margin, and femoral neck remodeling. Hip dysplasia has low-to-moderate quantitative heritability in dogs, while the contributing environmental and epigenetic influences are understood only marginally. Genomic, epigenetic, and environmental influences on hip joints of wild canids are not known. Potential population consequences of hip dysplasia, or hip dysplasia-like conditions, in free-living populations of wild animals, remain speculative. Possible concerns for affected individuals include reduced predatory and breeding efficiency, greater tendency to focus on local prey that are caught most easily, and greater risk as targets for predation. Progressive dissemination of hip joint diseases in a population could raise concerns about sustainability, altered size and density of prey populations, and local invasion by other predators. Our observations suggest a need for new research to better understand the biological nature of the disease(s) that these features represent, as well as suggesting new pathways for the studies of musculoskeletal disorders among Canidae.

Key words: Bone diseases, Hip dysplasia, Hip joint, Red fox, *Vulpes vulpes*

Introduction

Hip dysplasia (HD) is a common orthopedic disease of the domestic dog (*Canis lupus familiaris*). The accepted diagnostic phenotype in living subjects is radiographically visible subluxation of the femoral head (Figures 1, 2) (Henricson et al. 1966). Secondary progressive degenerative joint disease common, and is associated with synovitis, erosion of joint cartilage, increased joint fluid volume, elongated and edematous teres ligament, thickening and inflammation of the joint capsule, periarticular osteophyte formation, and pain (Riser 1973; Mayhew et al. 2002; Szabo et al. 2007). The combined effects of femoral head subluxation and subsequent degenerative joint disease are seen in the overt presentation of the living dog, wherein severe debilitation is not unusual.

Historically, HD was regarded as a quantitatively inherited disease of larger domestic dogs, having a recognized but vaguely understood environmental component. Today, it is recognized that phenotypic HD occurs in dogs of all sizes (Tsai and Murphy 2006; Karbe et al. 2012), humans (Beltran et al. 2013), and domestic cats (Langenbach et al. 1998; Murphy et al. 1999; Langenbach et al. 2001). Apparently dysplastic individuals are described occasionally in wild species (Douglass 1981), but the species spectrum of HD and its comparative pathobiology are not understood.

Morphological foundations for HD radiographic diagnosis have been reinforced by studies of domestic dog postmortem specimens (Henricson et al. 1966; Riser 1973). We use the latter basis, along with more recent research (Morgan 1987; Mayhew et al. 2002; Szabo et al. 2007), to describe hip joint pathology of the skeletal remains of a red fox (*Vulpes vulpes*) that are remarkably similar to skeletal features of HD in domestic dogs.

Methods

The skeletal remains of the 20th century adult red fox described in this report are curated at the Illinois State Museum Collections in Springfield, Illinois, as part of the zoological collections. The fox was free-roaming during life, and was presented to the museum following death from unrecorded cause(s). No additional information was available. The joints were disarticulated as a part of the skeletal clearing process. Acetabular features evaluated specifically included shape and depth, articular surfaces, medial and lateral articular margins, periarticular structure, and presence of osteophytes. Proximal femoral features evaluated specifically included femoral head shape, presence of circumferential femoral head osteophyte (CFHO), presence of caudal curvilinear osteophyte (CCO), and remodeling of the femoral neck (Riser 1975; Morgan 1987; Mayhew et al. 2002; Szabo et al. 2007). Hips also were evaluated as a joint unit by digitally apposing acetabular and femoral components, to estimate spatial relationships.

Observations were recorded by diagnosis, location, and degree. All features were photographed.

Results

Pathological observations of the acetabulae included mild central concavity of each lateral margin, resulting in reduced dorsal coverage of respective femoral heads (Figure 3); irregular dorsal acetabular margin (Figure 3); shallow acetabular depth; and prominently thickened medial and lateral (Figure 3) articular margins (osteophyte rims). The proximal femoral heads revealed caudal curvilinear osteophyte (CCO) (Figure 3); mild flattening (Figure 4); mild circumferential femoral head osteophyte (CFHO) (Figure 4); mild dorsally thickened femoral neck (Figure 4); and mild femoral neck remodeling (Figure 4). Photographs of a normally conformed grey fox (*Urocyon cinereoargenteus*) hip joint (Figure 5), and a normal red fox proximal femur (Figure 6), are included for species comparisons. The morphology of this red fox aligns with hip dysplasia, as it is understood in domestic dogs (Riser 1975; Morgan 1987; Mayhew et al. 2002; Szabo et al. 2007).

Other pathological skeletal observations included prominent articular margins of both ulnar distomedial coronoid processes, prominent medial and lateral periarticular margins of the distal right femur, supra-alveolar rim formation on the right and left lateral maxillae, and mild bilateral indication of periodontal disease of mandibular molars.

Discussion

The red fox, while being the largest of the American foxes, is nonetheless small, light, and gracile, with mature body weight between 3.0 and 8.0 kg. (Storm et al. 1976; Lariviere and Pasitschnial-Arts 1996). When hunting small prey, the red fox pounces to pin its victim with the forefeet, and then kills it with a bite. Somewhat larger prey, such as rabbits, are stalked and then attacked with a rush. (Seton 1923; Scott 1943; Cypher 2003). Given these carnivorous behaviors, high prevalence of surviving adults with HD-like hip pathology might not be expected, since significant orthopedic impairment limits the ability to compete for food, and could lead to very local focus on prey that are more easily caught. A dysplastic fox also might be more subject to predation, less able to compete reproductively, and less able to elude humans. A lesson from domestic dogs, however, is that affected individuals could survive long enough to enter breeding pools for periods of time.

Activity-related “wear and tear” joint pathologies, such as were observed on the proximal ulnae, and one distal femur, are not unexpected. These more minor features may be less limiting, as they appear frequently in foxes of

most species and various ages. Evidence of periodontal disease also is not unusual among canids, although its role in life processes of wild species requires further investigation. Based on the population frequencies of these minor pathologies in foxes generally, it is not likely that they are pathologically related to expression of the HD phenotype.

At present, multiple and extensively investigated radiographic phenotypes exist for recognizing HD in living domestic dogs, but they remain intensely controversial. (Leighton 2013). Thus, until studies further clarify the accuracy of two-dimensional radiographic phenotypes for representing three-dimensional hip joint pathology, applying these methods to HD research in living wild mammals should be done cautiously, particularly given risks associated with capture, transport, and anesthesia.

Examination of normal hip structures in *U. cinereoargenteus* and *V. vulpes* illustrates an additional morphological point. The near-normal grey fox (Figure 5) demonstrates a slight prominence at the acetabular lateral articular margin that corresponds anatomically to the larger osteoarthritic prominence seen in the affected red fox (Figure 1). The near-normal red fox proximal femur (Figure 6) demonstrates slight roughness at the margin of the articular surface, the site at which CFHO occurs (Figure 4). These comparisons suggest that sites of transition of tissue types or functions (margins of articular surfaces) and stress points (acetabular lateral articular border) may be biologically predisposed to pathological changes that progress gradually and covertly. Early stages of potential pathological changes, and whether these changes are recognized by current diagnostic imaging, are other areas that require new investigations.

Finally, quantitative inheritance necessarily implies contributing epigenetic or non-genetic components. It is not known how behavioral traits such as species-related hunting, foraging, and social interactions, compare among domestic and wild canids, with respect to possible influence on the HD phenotype. Likewise, influences on phenotypic HD that might be associated with nutritional state, chronological age, degenerative diseases of aging, and non-aging diseases, are not yet understood for wild canids. Thus, exploring population implications of recognizing HD in wild animals must await additional morphological and pathobiological studies. However, observations such as those reported here can suggest new approaches to understanding the biological history and quantitative genetics of HD in broader evolutionary context.

The Illinois State Museum Collections Center, Springfield IL, is acknowledged for assistance with using museum collections for this research. There are no conflicts of interest.

Literature Cited

- Beltran LS, Rosenberg ZS, Mayo JD, [DeTuesta MD](#), [Martin O](#), [Neto LP](#), [Bencardino JT](#). 2013. Imaging evaluation of developmental hip dysplasia in the young adult. *Am J Roentgenol* 200:1077-1088.
- Cypher BL. 2003. Foxes. In: *Wild Mammals of North America*, 2nd Ed., Feldhamer GA, Thompson BL, Chapman GA (editors). Johns Hopkins University Press, Baltimore, pp. 511-546.
- Douglass EM. 1981. Hip dysplasia in a timber wolf. *Vet Med Sm Anim Clin* 76:401-403.
- Henricson B, Norberg I, Olsson S.-E. 1966. On the etiology and pathogenesis of hip dysplasia: A comparative review. *J Sm Anim Pract* 7:673-688.
- Karbe GT, Biery DN, Gregor TP, Giger U, Smith GK. 2012. [Radiographic hip joint phenotype of the Pembroke Welsh Corgi](#). *Vet Surg* 41:34-41.
- Langenbach A, Green P, Giger U, Rhodes H, Gregor T, LaFond E, Smith G. 1998. Relationship of degenerative joint disease and laxity in the coxofemoral joint by use of distraction index and Norberg Angle measurement in a group of cats. *J Am Vet Med Assoc* 213:439-443.
- Langenbach A, Murphy TP, Smith GK. 2001. Hip Dysplasia. In: *Consultations in Feline Internal Medicine*, 4th Ed. WB Saunders, Philadelphia, pp. 592-599.
- Lariviere S, Pasitschniak-Arts M. 1996. *Vulpes vulpes*. *Mammal Species* 537:1-11.
- Leighton EA, McDonald-Lynch MB, Holle D, Biery DN, Gregor TP, Wallace ML, Smith GK. 2013. Efficacy of 30 years of selective breeding to eliminate hip dysplasia in service dogs at the Seeing Eye, Inc: Identifying the “Target Phenotype” to control a complex genetic trait. In: *Proceedings of the 8th International Working Conference*, San Antonio, TX, USA, pp. 13-16.
- Mayhew PD, McKelvie PJ, Biery DN, Shofer FS, Smith GK. 2002. Evaluation of a radiographic caudolateral curvilinear osteophyte of the femoral neck and its relationship to degenerative joint disease and distraction index in dogs. *J Am Vet Med Assoc* 220:472-476.
- Morgan JP. 1987. Canine hip dysplasia: Significance of early bone spurring. *Vet Radiol* 28:2-5.
- Murphy TP, Biery DN, Smith GK. 1999. Hip dysplasia in a group of 82 Maine Coon cats. In: *Proceedings of the 6th Annual Conference of the European Association for Veterinary Diagnostic Imaging*, Vienna, p. 87.
- Riser WH. 1973. The dysplastic hip: Its radiographic and histologic development. *J Am Vet Radiol Soc* 14:35-50.
- Riser WH. 1975. The dog as a model for the study of hip dysplasia: Growth, form, and development of the normal

- and dysplastic hip joint. *Vet Pathol* 12:224-234.
- Seton ET. 1923. The mane on the tail of the grey fox. *J Mammalogy* 4:180-182.
- Scott TG. 1943. Some food coactions of the northern plains red fox. *Ecol Mono* 13:427-479.
- Storm GL, Andrews RD, Phillips RL, Bishop RA, Siniff BD, Tester JR. 1976. Morphology, reproduction, dispersal and mortality of Midwestern red fox populations. *Wildl Mono* 49:1-82.
- Szabo SD, Biery DN, Lawler DF, Shofer FS, Powers MY, Kealy RD, Smith GK. 2007. [Evaluation of a circumferential femoral head osteophyte as an early indicator of osteoarthritis characteristic of canine hip dysplasia in dogs.](#) *J Am Vet Med Assoc* 231:989-992.
- Tsai KL, Murphy KE. 2006. [Clinical and genetic assessments of hip joint laxity in the Boykin spaniel.](#) *Can J Vet Res* 70:148-150.

Figure legends

Figure 1. Ventro-dorsal, legs-extended radiographic view of normal hip joint conformation (arrow).

Figure 2. Ventro-dorsal, legs-extended radiographic view of femoral head subluxation and moderate hip joint laxity (arrow).

Figure 3. Caudolateral view, digitally apposed right acetabulum and proximal femur in a red fox (*Vulpes vulpes*): Reduced acetabular dorsal coverage of the femoral head (short black arrows); irregular lateral acetabular border (long black arrow); thickened lateral acetabular periarticular margin (long white arrow); caudal curvilinear osteophyte (CCO, white arrowhead). Note CCO is continuous with CFHO.

Figure 4. Cranial view, right proximal femur: Mildly flattened femoral head (two white arrowheads); mild circumferential femoral head osteophyte (CFHO, short black arrow); mild dorsally thickened femoral neck (long white arrow); mild femoral neck remodeling (two medium black arrows).

Figure 5. Digitally apposed right acetabulum and proximal femoral head in a grey fox (*Urocyon cinereoargenteus*). Normal. Compare lateral articular margin (white arrow) to the same structure in Figure 1 (long black arrow).

Figure 6. Cranial view, left proximal femur, red fox (*Vulpes vulpes*). Normal. Compare articular margin (black arrows) to the same structure in Figure 2 (short black arrow).

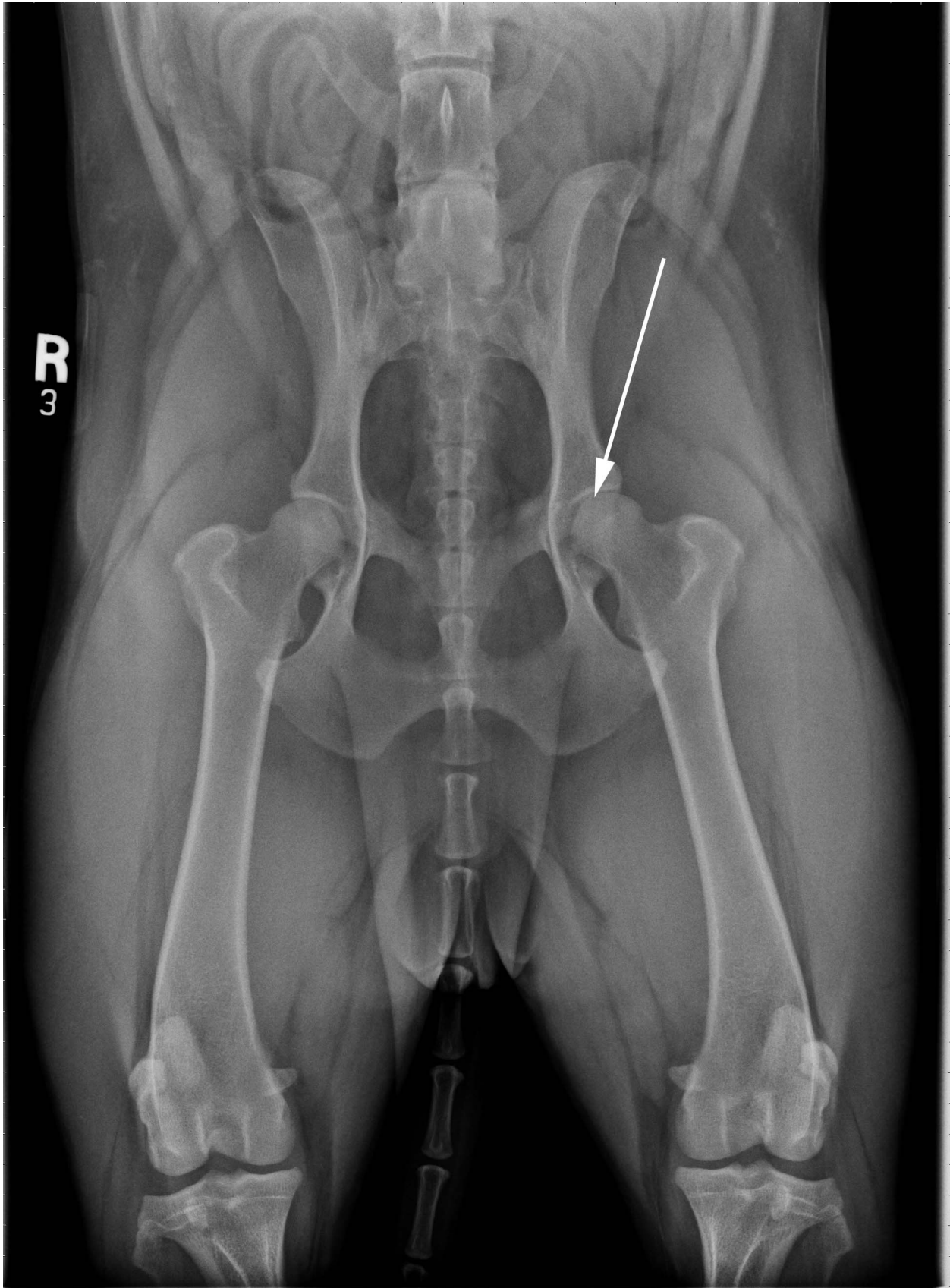


Figure 1: Ventro-dorsal, legs-extended radiographic view of normal hip joint conformation (arrow)

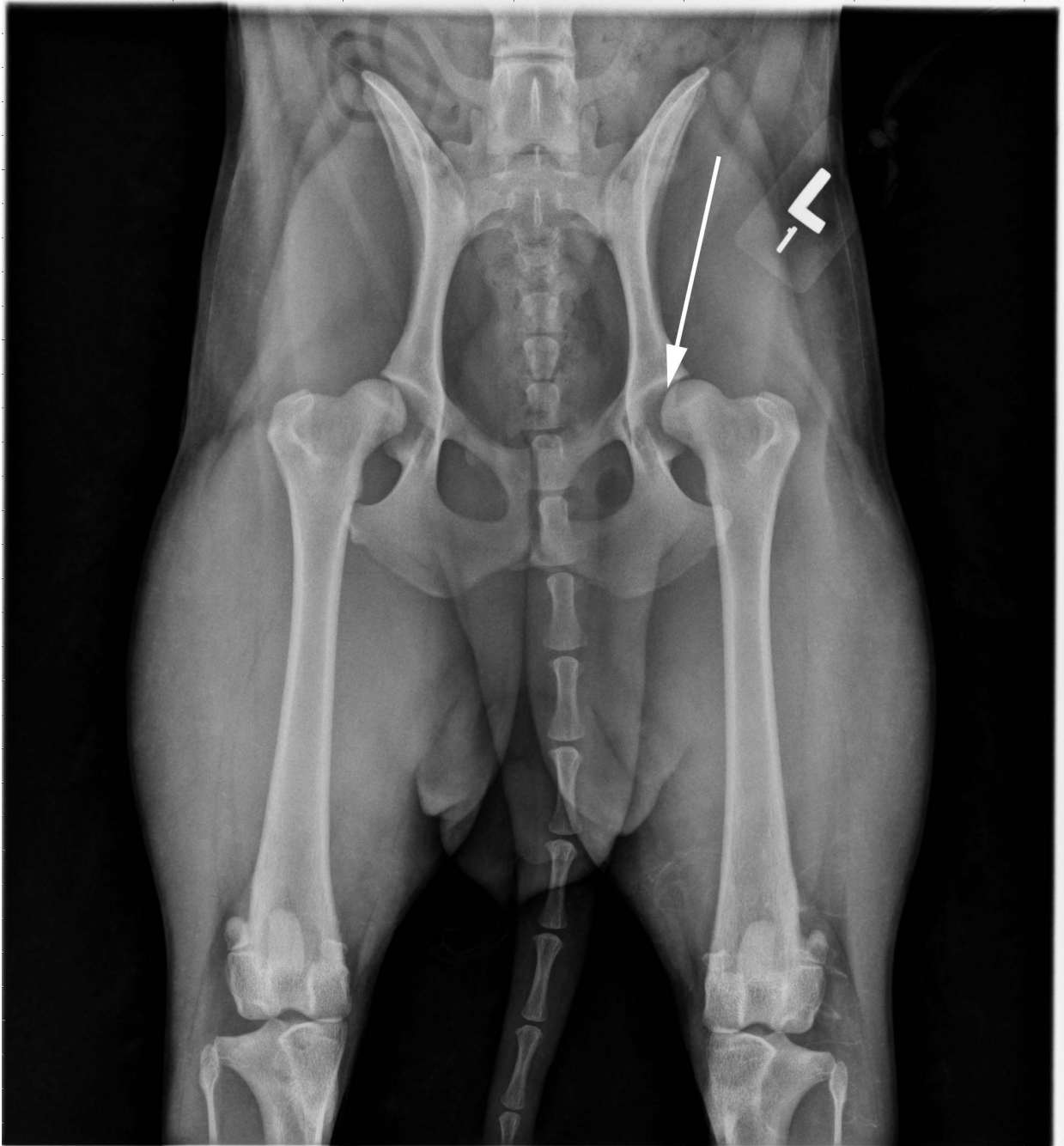


Figure 2: Ventro-dorsal, legs-extended radiographic view of femoral head subluxation and moderate hip joint laxity (arrow).

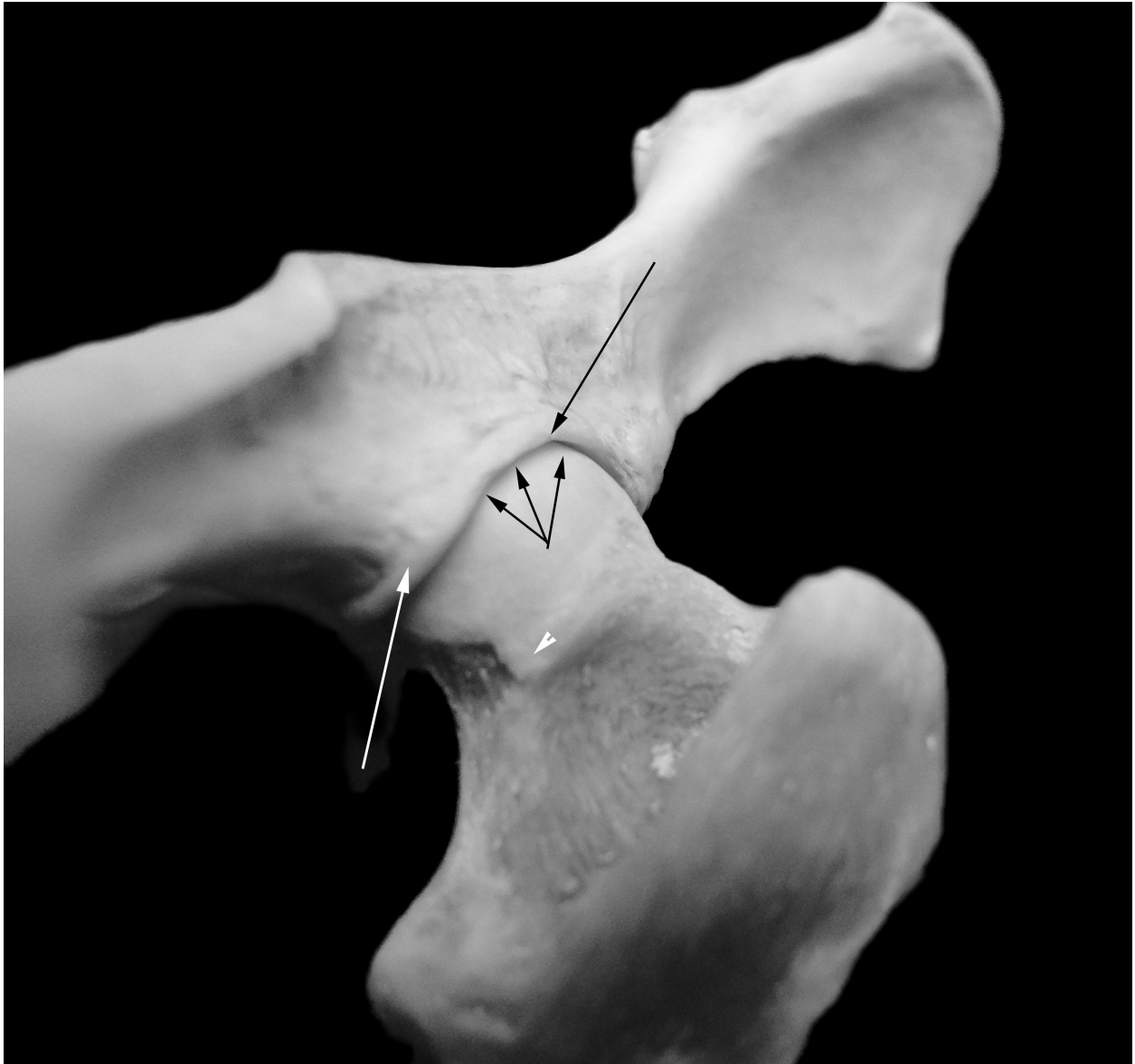

Figure 3: Caudolateral view, digitally apposed right acetabulum and proximal femur in a red fox (Vulpes vulpes): Reduced acetabular dorsal coverage of the femoral head (short black arrows); irregular lateral acetabular border (long black arrow); thickened lateral acetabular periarticular margin (long white arrow); caudal curvilinear osteopyte (CCO, white arrowhead). Note CCO is continuous with CFHO.

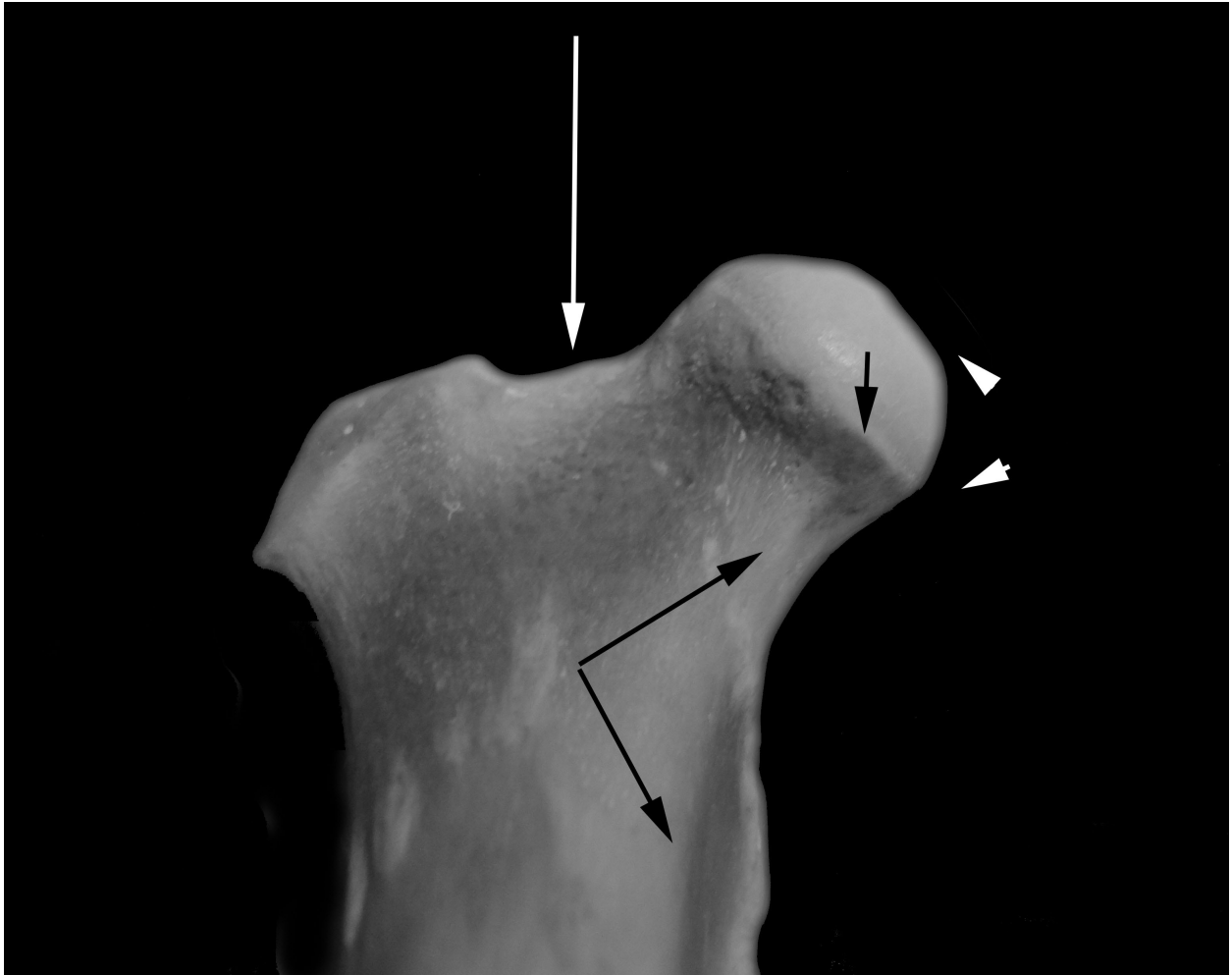


Figure 4: Cranial view, right proximal femur: Mildly flattened femoral head (two white arrowheads); mild circumferential femoral head osteophyte (CFHO, short black arrow); mild dorsally thickened femoral neck (long white arrow); mild femoral neck remodeling (two medium black arrows).

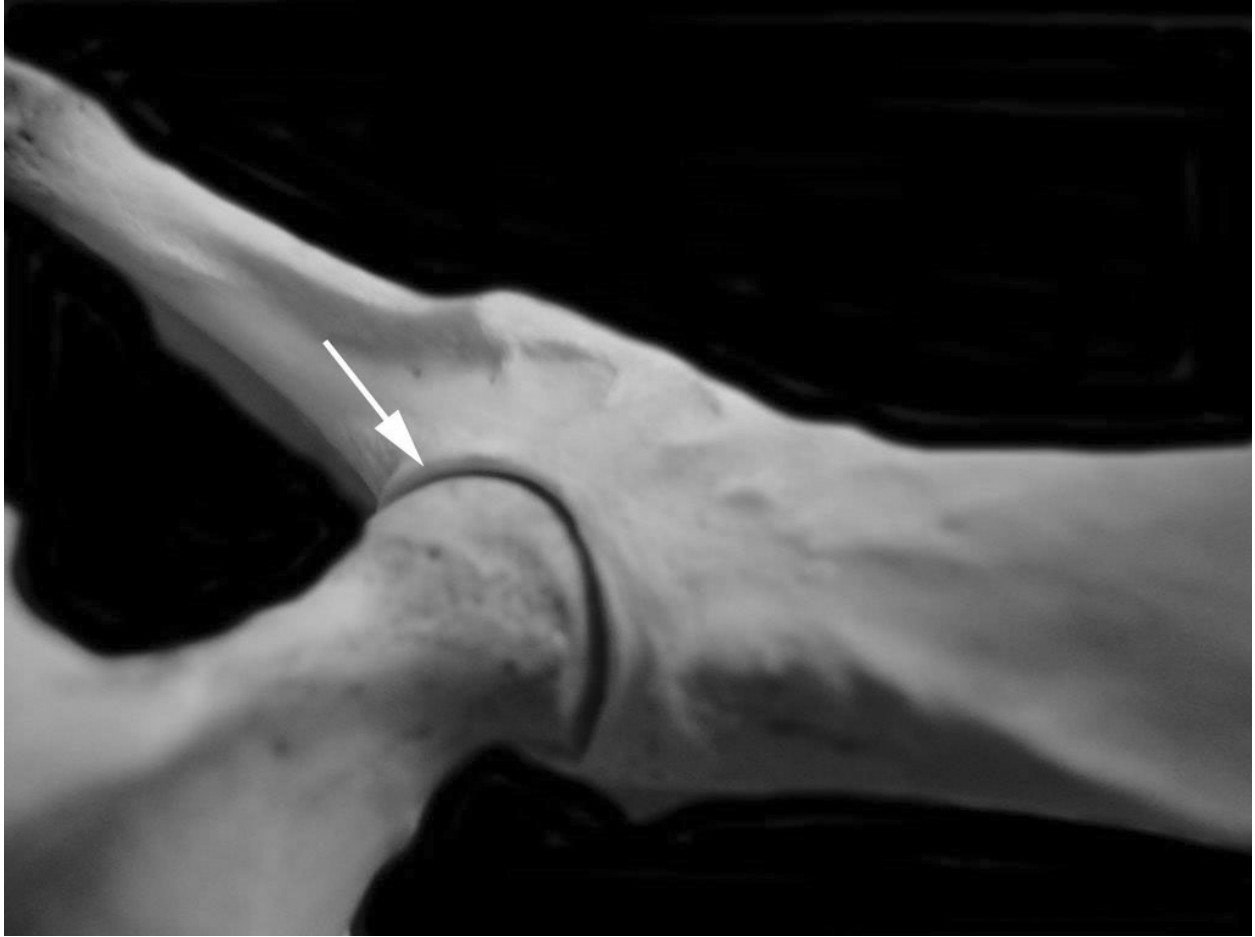

Figure 5: Digitally apposed right acetabulum and proximal femoral head in a grey fox (Urocyon cinereoargenteus). Normal. Compare lateral articular margin (white arrow) to the same structure in Figure 1 (long black arrow).

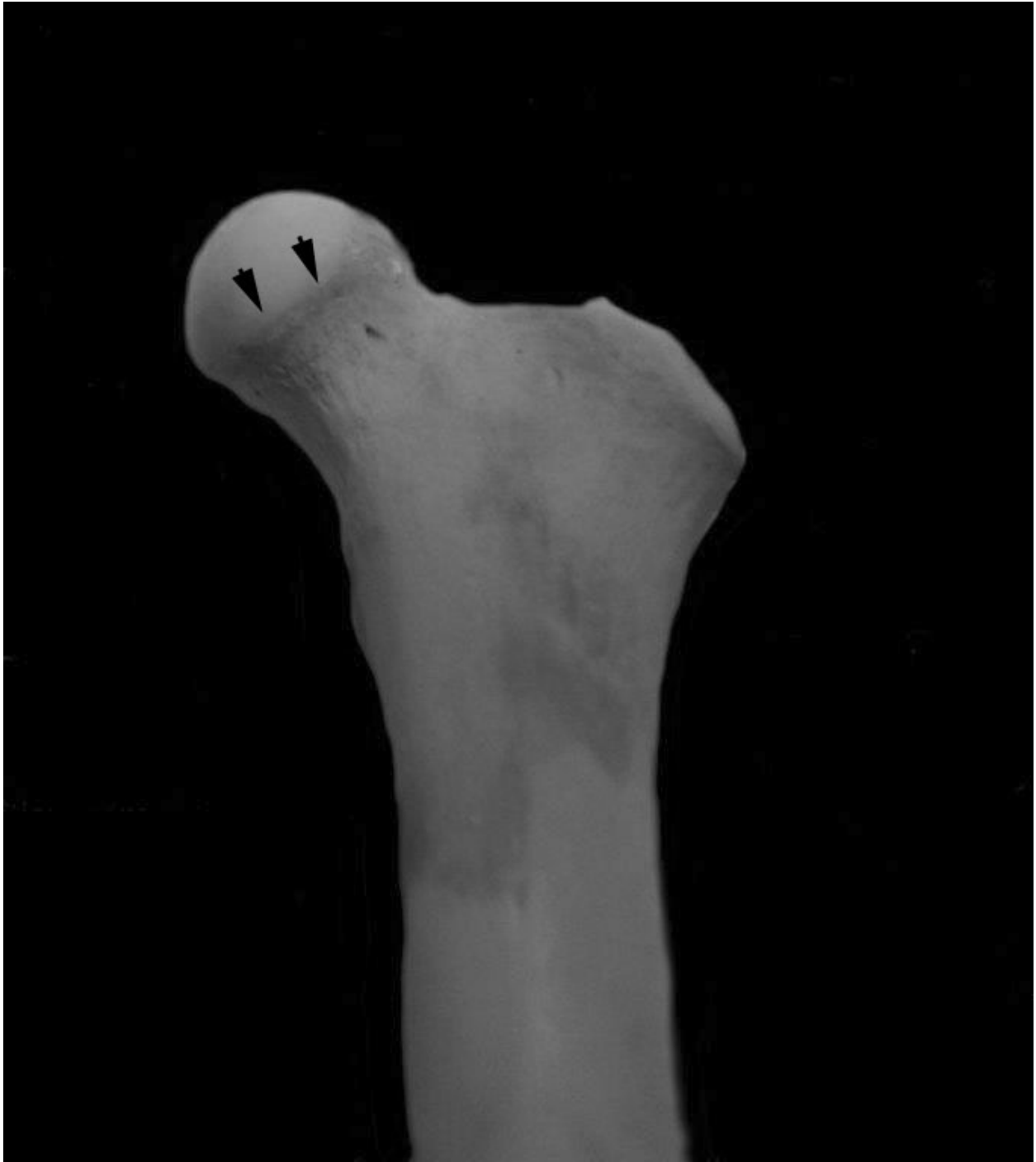

Figure 6: Cranial view, left proximal femur, red fox (Vulpes vulpes). Normal. Compare articular margin (black arrows) to the same structure in Figure 2 (short black arrow).